



SAUDI BOARD RESIDENCY TRAINING PROGRAM

Pediatric Dentistry

Part One Examination

Ex Examination Format:

1. Part I Examination of Saudi board certificate shall consist of one paper with 150 multiple-choice questions (single best answer out of four options). Up to 10% unscored items can be added for pretesting purposes.
2. If any other assessment format is used, the Central Assessment Committee must agree to its implementation.

Passing Score:

1. The passing score is 65%.
2. If the percentage of candidates passing the exam before final approval is less than 70%, the passing score can be lowered by one mark at a time aiming at achieving 70% passing rate or a score of 60% whichever comes first. Under no circumstances, may the score can be reduced below 60%.

Suggested References:

Below is a list of references in their current edition that are used for the examination.

1. Brennan P, Mahadevan V, Evans B. Clinical Head and Neck Anatomy for Surgeons.
2. Nanci A. Ten Cate's Oral Histology: Development, Structure and Function.
3. Daniel j, Chiego, jr. Essentials of Oral Histology and Embryology. A clinical approach.
4. Neville B, Damm D, Allen c, Chi A. Oral and maxillofacial Pathology
5. Tortora, Funk, and Case. Microbiology; an Introduction.
6. White, S.C. and Pharoah, M.J. Oral Radiology, Principles and Interpretation.
7. Center for Disease control and Prevention Guidelines for Infection Control in Dentistry
8. Kliegman, R. M., Stanton, B., Geme, J. & Schor, N. Nelson Textbook of Pediatrics
9. Dean, Mcdonald, Avery. Dentistry for the child and adolescent.



10. Casamassimo, P.S., Fields, H.W., McTigue, D.J., & Nowak, A.J. Pediatric Dentistry: Infancy Through Adolescence.
11. Andreasen, Bakland, Flores, Andreasen, Andersson. Traumatic Dental Injuries
12. Hargreaves, K. & Berman, L. Cohen's Pathways of the Pulp
13. Malamed SF. Inhalational Sedation: techniques of administration. In: Sedation: A Guide to Patient Management.
14. American Academy of Pediatric Dentistry Reference Manual <http://www.aapd.org/media/policiesguidelines>
15. Crash courses, Journal club, and Book Review Materials
16. Can MEDS physician Competency framework, Edition 2015, The Royal College of Physicians and Surgeons of Canada
17. Introduction to clinical Research for residents
18. Professionalism and Ethics, Handbook for Residents, Practical guide, Prof. James Ware, Dr. Abdulaziz Fahad Alkaabba, Dr. Ghaiath MA Hussein, Prof. Omar Hasan Kasule, SCFHS, Latest Edition
19. Essentials of Patient Safety, SCHS, Latest Edition

It can be downloaded from the Saudi Commission's

[website:http://www.scfhs.org.sa/en/MESPS/TrainingProgs/EduMatActiv/](http://www.scfhs.org.sa/en/MESPS/TrainingProgs/EduMatActiv/)

Note:

This list is intended for use as a study aid only. SCFHS does not intend the list to imply endorsement of these specific references, nor are the exam questions necessarily taken solely from these sources.



Blueprint Outlines:

No.	Sections	Percentage (%)
1	Basic Sciences	20%
2	Infection Control Guidelines	5%
3	Oral and Maxillofacial Radiology	5%
4	Pediatric Medicine	5%
5	Oral Diagnosis/Oral Pathology/Oral Medicine	15%
6	Prevention and Anticipatory Guidance	10%
7	Child Development, Psychology and Behavior Guidance	10%
8	Analgesia/Anxiolysis Nitrous Oxide Inhalational Sedation	5%
9	Restorative Dentistry	5%
10	Pulp Therapy	5%
11	Orofacial Trauma	5%
12	Research, Ethics and Professionalism and Patient Safety	10%
Total		100%

Note:

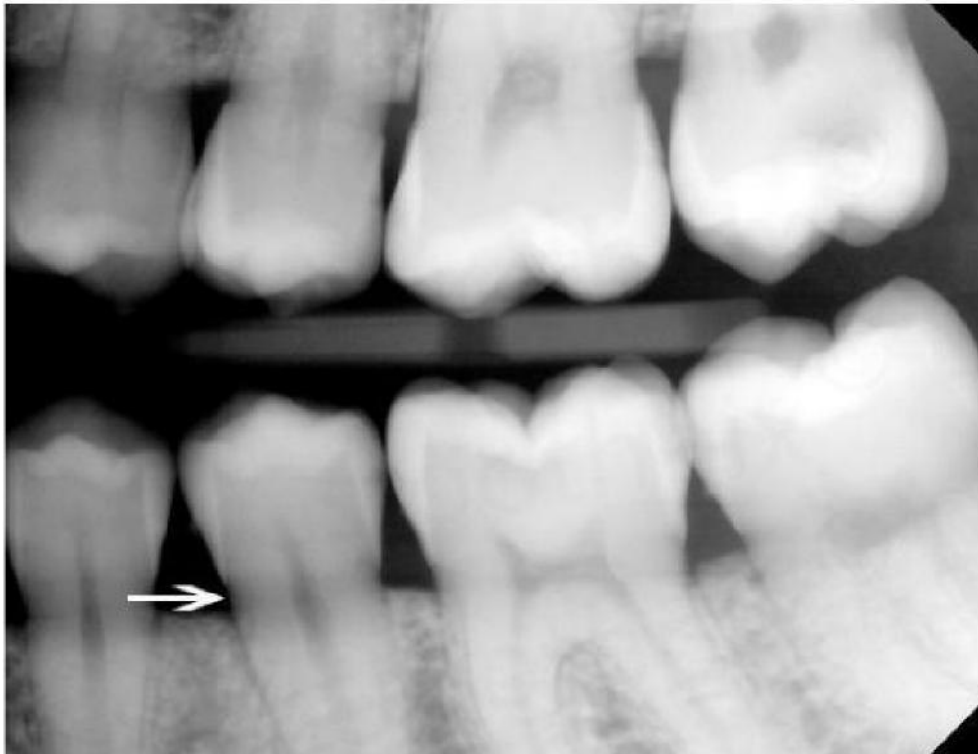
- Blueprint distributions of the examination may differ up to +/-3% in each category.
- Percentages and content are subject to change at any time. See the SCFHS website for the most up-to-date information.



Example Questions

EXAMPLE OF K2 QUESTIONS

Question 1



On a radiographic interpretation of a bitewing of a 14-year-old boy with diabetes mellitus Type I, the dentist saw diffused radiolucent areas with ill-defined borders on the mesial and distal aspects of teeth in the cervical regions between the edge of the enamel cap and the crest of the alveolar ridge on a premolar bitewing film. There is no pain and the teeth are sound and intact in clinical examination.

Which of the following is the most likely diagnosis?

- A. Mach bands
- B. External cervical root resorption
- C. Cervical burnout
- D. Processing or technique error on the film



EXAMPLE OF K1

Question 2

Which of the following muscles is supplied by the facial nerve?

- A. Orbicularis oculi
- B. Masseter muscle
- C. Temporalis
- D. Lateral pterygoid

